

# *A Rare Case of Mucoepidermoid Carcinoma of the Nasal Septum*

*Alano Nunes Barcellos\**, *Carolina Pimenta Carvalho\*\**, *Daniel Caldeira Teixeira\*\*\**,  
*Juliana Altavilla van Petten Machado\*\*\*\**, *Aureliano Carneiro Barreiros\*\*\*\**,  
*Taiane Nunes Barcellos\*\*\*\*\**.

\* Specialist in Otorhinolaryngology at ABORL-CCF Otorhinolaryngologist.

\*\* Specialist in ORL 3<sup>rd</sup> Year Specialization.

\*\*\* In Course for Specialization in ORL 3<sup>rd</sup> Year Specialization.

\*\*\*\* Specialist in Otorhinolaryngology at ABORL-CCF Preceptor of ORL Specialization in ORL of Hospital Socor - Belo Horizonte / MG.

\*\*\*\*\* Student of Medicine in the College of Barbacena - MG (4<sup>th</sup> year of graduation in medicine).

Institution: Serviço de Otorrinolaringologia e Cirurgia Cérvico-Facial do Hospital Socor Belo Horizonte - MG.  
Belo Horizonte / MG - Brazil.

Mail address: Alano Nunes Barcellos - Rua Juiz de Fora, 115/1301 - Bairro: Barro Preto. Belo Horizonte / MG - Brazil - Zip code: 30180-060 - Fax: (+55 31) 3832-1647  
- E-mail: dr\_alano@yahoo.com.br

Presented as a poster in the 5th Triological Congress of Otorhinolaryngology, during the 6<sup>th</sup> through the 9<sup>th</sup> of June 2007, in Brasília / DF.

Article received on November 3, 2007. Approved on August 23, 2008.

## SUMMARY

- Introduction:** Mucoepidermoid carcinoma is the most common malignant neoplasm of the salivary glands, and the parotid is the main site of attack. It also occurs in the minor salivary glands from the nasal cavity to the lungs. Nasal location of the mucoepidermoid carcinoma is extremely rare. There is little literature on similar cases.
- Objective:** To report a case of mucoepidermoid carcinoma of the right nasal septum, and cover general aspects of the pathogenesis, diagnosis, therapy, and post-operative follow-up.
- Case Report:** We present a case of a 32-year-old patient with a history of nasal obstruction, epistaxis and tumoration in the right nasal cavity. The biopsy revealed it was a mucoepidermoid carcinoma. The tumor was surgically removed using endoscopes with associated complementary radiotherapy. The anatomopathological analysis classified it with a high degree of malignancy. We obtained remission of the symptoms and without subsequent recurrence.
- Conclusion:** Tumor nasal masses should be studied with imaging and histopathology examinations. We may discover rare malignant nasal tumors.
- Keywords:** mucoepidermoid carcinoma, nasal septum, nasal mucosa, surgery, radiotherapy, pathology.

## INTRODUCTION

The mucoepidermoid carcinoma is the salivary glands most frequent malignant tumor and it affects the major and minor salivary glands (1,2). It's the most common malignant tumor in the parotid (60-70% cases) (1,2). Its origin is the epithelium of the glandular excreting duct, and it may also develop in the nasal cavity minor salivary glands, maxillary sinuses, nasopharynx, oropharynx, larynx, vocal cords, trachea, lungs and lacrimal glands (1, 3, 4).

Malignant tumor located in the nasal cavity and paranasal sinuses are extremely rare and correspond to about 3% of the head and neck neoplasms. In the United States, there is an estimate of less than one case per 100000 inhabitants (5,6). The literature mentions a few cases of nasal septum affection. Out of these cervical-facial tumors, only 10% come from the salivary glands located in the nasosinusal mucosa, and their main subtypes, in frequency order are cystic adenoid, adenocarcinoma and mucoepidermoid (5) (Table 1). In a study carried out by CALDERON-GARCIDUEÑAS et al. (6), with 256 patients with nasosinusal malignant neoplasm, no case of mucoepidermoid was described in this location.

## CASE REPORT

A 32-year-old, female, melanodermic patient. Presented with a history of nasal obstruction, frequent fluid rhinorrhea and epistaxis in the right nasal cavity for about 2 years. She mentioned having eliminated a reddish mass from this nostril about 1 year ago during a sneezing crisis.

Upon otorhinolaryngologic exam: the right nasal cavity had a tumor mass with verrucous, rose-colored, soft aspect, bleeding upon manipulation, non-pulsating, implanted in the nasal septum, obstructing the respiratory passage.

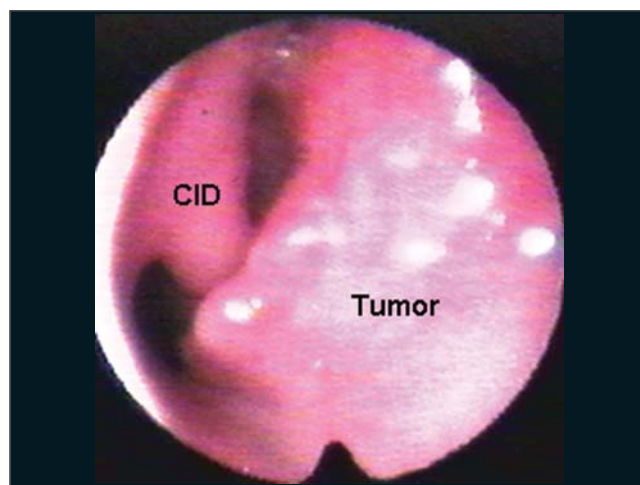
The nasofibroscopy (Picture 1) revealed a vegetating lesion originated in the nasal septum frontal region and the ground and lateral wall were preserved. Computerized Tomography of the face sinuses (Picture 2) showed affection in the right nasal septum at areas II, III and IV of Cottlè. The cervical CT revealed reactional lymph-node-megaly.

The tumoral biopsy revealed Mucoepidermoid Carcinoma. The tumor was classified with T1, N0, M0.

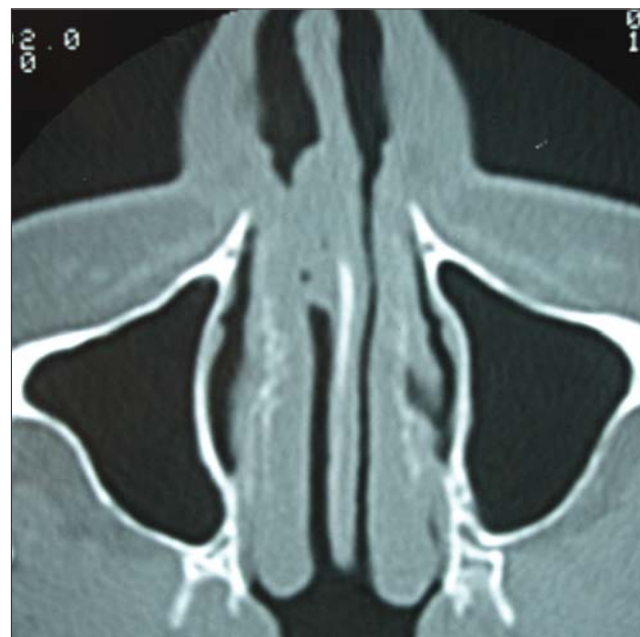
The right nasal cavity endoscopy during operation (Picture 3) revealed exiguous upper margin, that affected the septum above the retraction angle. She was submitted

**Table 1. Epithelial line tumors.**

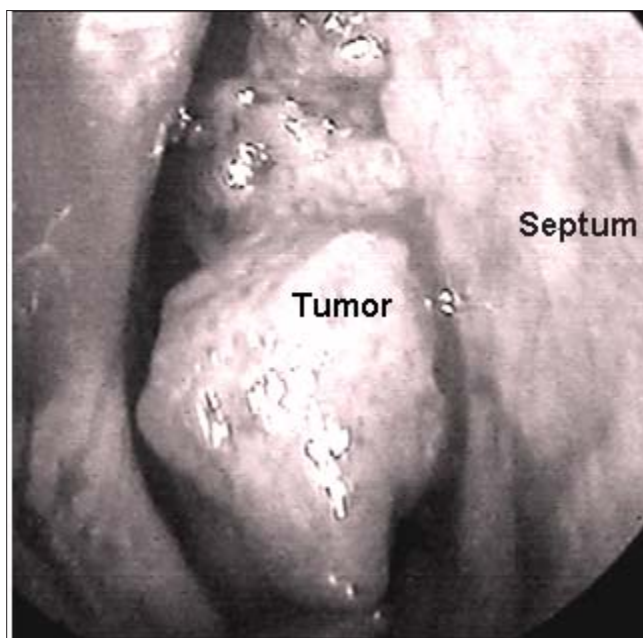
Squamous cells carcinoma
Adenocarcinoma
Undifferentiated carcinoma
Lymphoepithelial carcinoma
Melanoma
Glandular carcinoma:
a) malignant mixed tumor;
b) cystic adenoid carcinoma;
c) mucoepidermoid carcinoma.
Metastatic carcinomas (mamma, kidney, lung, prostate)



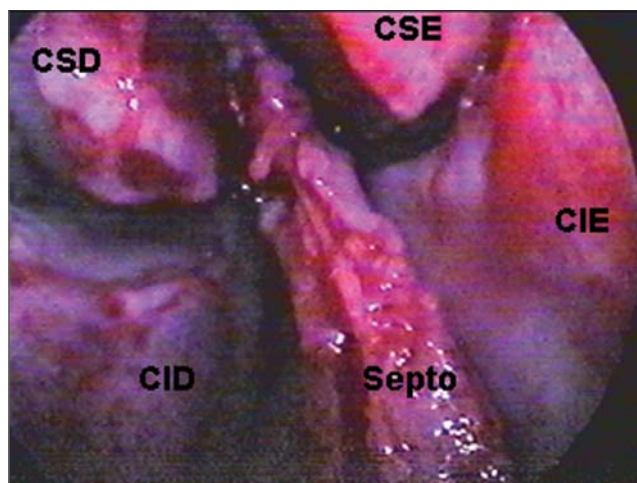
**Picture 1.** Mucoepidermoid Carcinoma of the Nasal Septum. Nasal Endoscopy CID: right lower infundibulum.



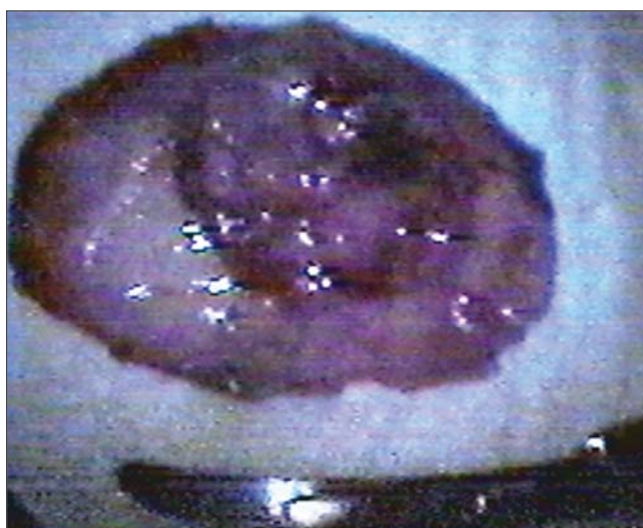
**Picture 2.** Imaging exam of the mucoepidermoid carcinoma of nasal septum. Axial tomography of the face sinuses. Pre-operative Right septum tumoration.



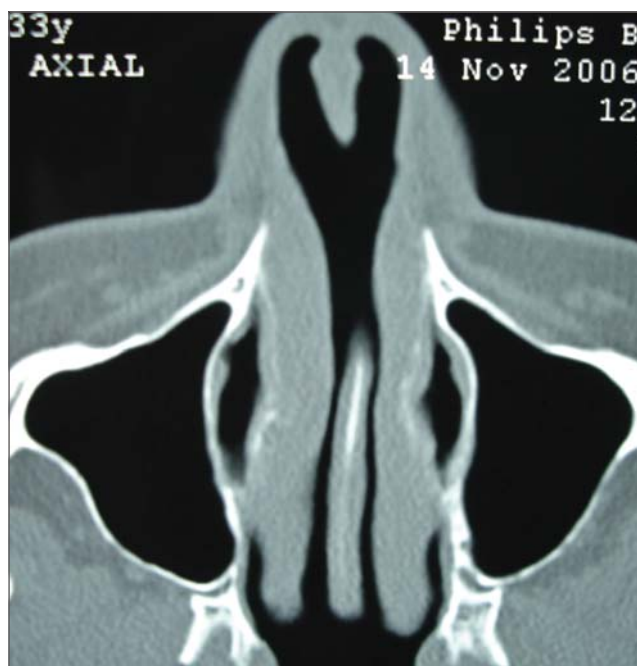**Picture 3.** Mucoepidermoid Carcinoma of the Right Nasal Septum. Endoscopic view during operation.



**Picture 4.** Septum carcinoma resection. Videoendoscopic surgical site. CID: right lower infundibulum. CIE: left lower infundibulum. CSD: right upper infundibulum. CSE: left upper infundibulum.



**Picture 5.** Septum carcinoma resection. Dried surgical part.



**Picture 6.** Optical microscopy exam of the mucoepidermoid carcinoma of nasal septum. Microscopy (HE 200 x and 100 x).

to surgery for the tumor exeresis, with endonasal access (Picture 4), associated with the nasal dorsum displacement. The tumor was removed in a single and wide block, including the septum cartilage and counter-lateral mucosa, which resulted in a wide perforation of the septum (Pictures 4,5) and the cartilaginous septum roof with about 0.5 mm. The safety margins were macroscopically normal, and were confirmed by freezing exam in the intraoperative.

The anatomopathological exam (Picture 6) revealed high grade malignancy mucoepidermoid carcinoma (Table 2) with 1.6x1.5x0.3 cm, removed with free surgical margins. Septum cartilage without tumor infiltration.

She was forwarded to the Oncology Service for complementary radiotherapy.

Postoperative tomography shows the dry area



**Table 2.** Mucoepidermoid graduation histological criteria (Ellis & Auclair - 1991)

Histological Parameter	Scoring
Intracystic component < 20%	+ 2
Presence of neural invasion	+ 2
Presence of necrosis	+ 3
Mitosis ( <sup>3</sup> 4/ 10 large increase fields)	+ 3
Presence of anaplasia	+ 4
<hr/>	
Histological Grade	Scoring
Low malignancy grade	0 to 4
Intermediate malignancy grade	0 to 6
High malignancy grade	7 to 14

(Pictures 7, 8). There is no sign of sealing in the nasal dorsum, even after radiotherapy.

She is in the 3<sup>rd</sup> year of follow-up, without local, regional or remote recurrence signals.

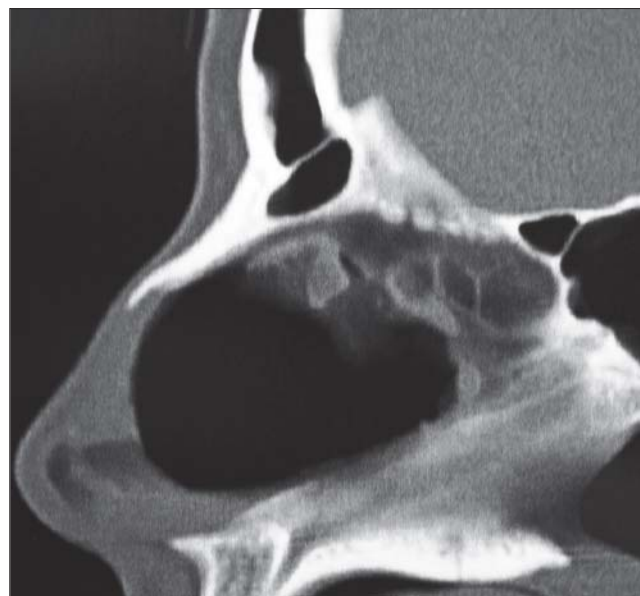## DISCUSSION

The mucoepidermoid carcinoma corresponds to 6 to 9% of all salivary glands tumors (3), and was found mainly in intraoral major and minor salivary glands. About 10% of the mucoepidermoid carcinoma cases occur out of the major salivary glands. The difficulty to study these unusual sites is the scarcity of studies and publications (1,3).

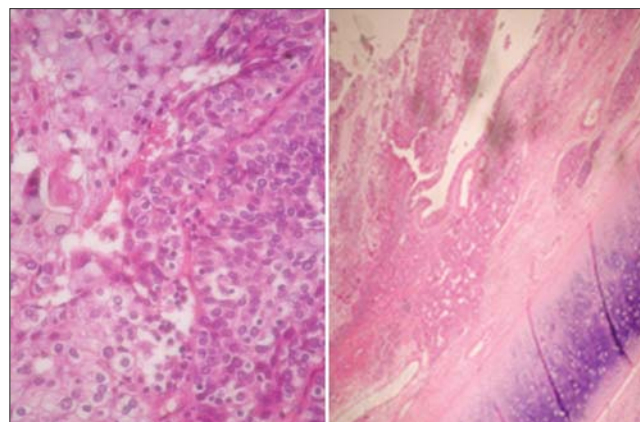
The nasal cavity and the paranasal sinuses are uncommon regions for malignant lesions. The main nasosinusal malignant tumor is the squamous cell carcinoma. Out of glandular tumors, the mucoepidermoid is the third in frequency, minor than the cystic adenoid and adenocarcinoma, respectively (5,6). Studies show that 0.6% of all salivary glands tumors are nasosinusal mucoepidermoid. When we consider all the mucoepidermoid tumors, 4.8% are nasosinusal (4).

The mucoepidermoid carcinoma is not frequent in the first decade of life, and has an incidence increase in young adults (3). As far as sex is concerned the studies are conflictive: some believe there is no predilection (1), others state preference for the feminine sex (60.2%) (3). As procatartic factors we include exposure to ionizing radiation, previous RT, nickel refinery, chemical solvents, leather, sawing, formaldehyde, pollution (6). The patient worked in a beauty salon with chemical stain and formol.

They appear as single mass, painlessly and of progressive and dragging growth (1,3). Generally, the



**Picture 7.** Imaging exam after surgical resection. Postoperative axial tomography of the dried septum area.



**Picture 8.** Imaging exam after surgical resection. Postoperative sagittal tomography of the dried septum area.

tumors in the nasal cavity are found earlier than the paranasal ones, due to their symptoms (1,5). The hidden metastasis incidence is low.

Histologically, the mucoepidermoid carcinoma is characterized by the presence of mucous, squamous and intermediate cells (with epidermoid metaplasia) (3,4). The pattern is cystic or cystic papillary (3). They may be classified into low, intermediate or high malignancy grade based on five parameters: proportion of cystic and solid elements, neural invasion presence, necrosis, anaplasia and mitotic rate (1,4) (Table 2). In spite of having been histologically classified with high malignancy grade, it clinically presented an indolent behavior.

The treatment is based on the tumor malignancy grade, tumor extension and the patient's general conditions. Wide surgical resection should be carried out, followed of post-operative radiotherapy for the intermediate and high grades, and only low grade tumors should be surgically operated (1,4). Cervical emptying should be performed in cases with regional metastases, advanced clinical staging or high histological grade (1,3). Chemotherapy has been suggested for high grade carcinomas for they have sensitivity similar to squamous cells carcinomas (3). In this case, we opted for not making excavation of the ganglions and maintained cervical CT.

The prognosis is influenced by the tumor grade, osseous invasion, absence of tumor in the surgical margins, age of 60 years or older, pain, cervical metastasis and facial paralysis. Low grade tumors allow 90% of survival within 10 years and the high grade tumors allow 42% (4).

---

### CONCLUSION

---

The nasal tumor masses must be studied with imaging exams and histopathology.

The computerized tomography reveals the limits, mass origin and exclude tumors too vascularized - nasoangiofibroma or in communication with the SNC - meningoceles, esthesioneuroblastoma. The nasal endoscopy complements the study in the identification of the tumor implantation.

The tumor biopsy may surprise with a malignant neoplasia diagnosis, and makes the surgical planning suitable to cure it.

---

### BIBLIOGRAPHICAL REFERENCES

---

1. Pires FR, Alves FA, Almeida OP, Kowalski LP. Carcinoma mucoepidermóide de cabeça e pescoço: estudo clínico-patológico de 173 casos. *Rev Bras Otorrinolaringol.* 2002, 68(5):679-84.
2. Devita VT, Hellman S, Rosenberg SA. Cancer of the Head and Neck. In: *Cancer - Principles & Practice of Oncology*, 5th ed. Philadelphia: Lippincott-Raven Publishers; 1997, p. 833.
3. Salazar CM, Saa J, Sánchez-Jara MR, García JL, González M. Carcinoma mucoepidermóide de vestíbulo nasal. *Acta Otorrinolaring Esp.* 2000, 51(7):729-32.
4. Thomas GR, Regalado JJ, McClinton M. A rare case of mucoepidermóide carcinoma of the nasal cavity. *Ear Nose Throat J.* 2002, 81(8):519-22.
5. Mendonça VF, Carvalho ACP, Freitas E, Boasquevisque EM. Tumores malignos da cavidade nasal: avaliação por tomografia computadorizada. *Radiol Brás.* 2005, 38(3):175-80.
6. Calderón-Garcidueñas L, Delgado R, Calderón-Garcidueñas A, Meneses A, Ruiz LM, Garza J, Acuna H, Villarreal-Calderón A, Raab-Traub N, Devlin R. Malignant neoplasms of the nasal cavity and paranasal sinuses: A series of 256 patients in México City and Monterrey. Is air pollution the missing link? *Otolaryngol Head Neck Surg.* Apr. 2000, 122:499-508.